

Collagen Crosslinking After Radial Keratotomy

Uri Elbaz, MD, Sonia N. Yeung, MD, PhD, FRCSC, Setareh Ziai, MD, FRCSC, Alejandro D. Lichtinger, MD, Noa Avni Zauberman, MD, MHA, Yakov Goldich, MD, Allan R. Slomovic, MD, FRCSC, and David S. Rootman, MD, FRCSC

Purpose: The aim of this study was to report the outcomes of corneal collagen crosslinking (CXL) after previous radial keratotomy (RK) in patients with decreasing visual acuity and/or diurnal visual fluctuations.

Methods: The charts of all patients who had undergone CXL because of a worsening corrected distance visual acuity (CDVA) and/or diurnal visual fluctuations after RK were reviewed retrospectively. Uncorrected distance visual acuity, CDVA, manifest refraction, and corneal topography were recorded preoperatively and at 1, 3, 6, and 12 months after the procedure.

Results: Nine eyes of 6 patients that had undergone an RK 15 to 23 years before the CXL were included in the study. In 5 patients (8 out of 9 eyes), discontinuation of diurnal visual fluctuation was reported between 6 and 12 months after the CXL. The mean uncorrected distance visual acuities pre and 12 months after the CXL were 0.7 logarithm of the minimum angle of resolution (logMAR) and 0.6 logMAR, respectively ($P = 0.3$). The mean CDVAs pre and 12 months after the CXL were 0.2 logMAR and 0.1 logMAR ($P = 0.5$), respectively. The mean average keratometry pre and 12 months after the CXL were 40.1 and 39.1 diopters ($P = 0.06$), respectively. The mean corneal astigmatism values pre and 12 months after the CXL were 2.3 and 1.9 diopters ($P = 0.06$), respectively. The mean manifest refraction spherical equivalents (MRSEs) before and 12 months after the CXL were +1.4 and +2.5 ($P = 0.1$), respectively.

Conclusions: CXL is a safe and effective method to restore corneal stability in eyes with a history of RK. However, some of the effect that was achieved at the 6-month visit was blunted at the 12-month visit. Therefore, a longer follow-up is necessary to validate these findings.

Key Words: radial keratotomy, corneal collagen crosslinking, RK, CXL

(*Cornea* 2014;33:131–136)

Received for publication August 13, 2013; revision received October 18, 2013; accepted October 28, 2013. Published online ahead of print December 16, 2013.

From the Department of Ophthalmology, Yonge-Eglinton Laser Center, Toronto Western Hospital, University Health Network, Toronto, ON, Canada. The authors have no funding or conflicts of interest to disclose.

Dr U. Elbaz is a recipient of the Schwartz Reisman Fellowship, Toronto, ON, Canada, for 2012 to 2013.

Reprints: Uri Elbaz, Department of Ophthalmology, Toronto Western Hospital, University of Toronto, Toronto, ON, Canada (e-mail: urielbaz@gmail.com). Copyright © 2013 by Lippincott Williams & Wilkins

In the early 1990s, photorefractive keratectomy (PRK) and laser-assisted in situ keratomileusis (LASIK) replaced radial keratotomy (RK) as the most common refractive procedure for vision correction.

One of the most frequent complications of RK is a hyperopic shift that can occur anytime between 6 months and 10 years postoperatively in approximately 43% of the patients.^{1–3} Treating this RK-induced hyperopic shift poses a challenge to the refractive surgeon. Both LASIK^{4,5} and PRK^{6–8} have been reported for the treatment of the hyperopic shift that occurs after RK, with variable results. Both surgeries have higher complication rates in this subpopulation. Specifically, LASIK over RK may result in various complications such as incision rupture, multiple button holes in the flap,^{9,10} epithelial ingrowth,¹¹ and a higher risk of developing iatrogenic corneal ectasia. There is a high rate of occurrence of haze in patients who have undergone PRK over RK.¹² In addition to these complications, this RK-induced hyperopic shift may continue to progress, especially after additional refractive surgery whereby biomechanical stability is challenged a second time. Therefore, the outcome of refractive surgery of any kind may be short lasting and unpredictable.

Another significant and troublesome complication post-RK is visual fluctuation caused by variations in corneal hydration and intraocular pressure (IOP) throughout the day.¹ This may also progress (and even accelerate) after refractive surgery as a result of the same biomechanical disruption.

Our study focuses on the outcomes of corneal collagen crosslinking (CXL) for RK-operated patients experiencing corneal instability reflected as decreasing vision and/or diurnal fluctuations in vision. Our hypothesis of potential corneal stabilization of post-RK eyes after CXL is founded on the encouraging outcomes reported after CXL in keratoconic eyes.¹³ If keratoconus (KC) progression can be halted and stabilized after CXL, a similar result can potentially be achieved in post-RK eyes experiencing visual fluctuation and a hyperopic shift. A stiffening of the cornea in post-RK eyes would induce stability of corneal parameters and subsequently of vision; the cornea will be less amenable to variations in the hydration status and curvature changes secondary to IOP fluctuations.

PATIENTS AND METHODS

This retrospective chart review was approved by the institutional research ethics committee at the University

Health Network, Toronto, ON, Canada. Nine eyes of 6 patients who presented with decreased vision 15 to 23 years after RK underwent CXL and were followed up for at least 12 months after the procedure. Informed consent for the CXL was obtained from all the patients before the procedure. Uncorrected distance visual acuity (UDVA), manifest refraction, corrected distance visual acuity (CDVA), IOP, pachymetry, and corneal topography and tomography were recorded before and at 1, 3, 6, and 12 months after the CXL. Topography data were recorded using the OPD II or III scan (Nidek, Japan), and tomography data were recorded using the Pentacam (Oculus, Germany). Crosslinking was conducted under sterile conditions using the Dresden protocol¹⁴ as follows: the patient's eye was anesthetized with proparacaine hydrochloride 0.5% (Alcaine, Alcon Laboratories, Inc, Mississauga, Canada). An 8-mm diameter area of the corneal epithelium was removed using 50% alcohol for 5 seconds to allow better diffusion of riboflavin into the stroma. After epithelial removal, single-use isotonic eye drops of 0.1% riboflavin and 20% dextran solution (Habers pharmacy, Toronto, ON, Canada) were instilled every 2 minutes for 30 minutes. Ultraviolet-A (UVA) irradiation was performed using an optical system (UV-X; Peschke Meditrade GmbH) with a light source consisting of an array of UV diodes (365 nm). Irradiance was performed for 30 minutes. During the period of UVA exposure, riboflavin solution was applied every 2 minutes to saturate the stroma. At the end of the procedure, a silicone-hydrogel bandage contact lens was applied and left in place until full corneal reepithelialization occurred, typically on day 4. Postoperatively, the patients were given a combination of antibiotic and corticosteroid drops (moxifloxacin 0.5%, Vigamox; Alcon Laboratories, Inc; and dexamethasone 0.1%, Maxidex, Alcon Laboratories, Inc) 4 times daily until the removal of the bandage contact lens. After the removal of the contact lens, the moxifloxacin was discontinued, and the dexamethasone was tapered down over the next 2 weeks. The patients were encouraged to use preservative-free artificial tears at least 4 times daily. The patients were followed up on the day after the procedure, at 1 week and 1, 3, 6, and 12 months postoperatively.

Statistical Analysis

Geometric visual acuity was converted to the logarithm of the minimum angle of resolution (logMAR) units, and manifest refraction was converted to spherical equivalent refraction where appropriate. The paired *t* test was used to compare the LogMAR visual acuity and the spherical equivalent before and after CXL. Statistical analysis was performed with SPSS software version 15.0 for Windows (SPSS, Inc, Chicago, IL), and a *P* value of <0.05 was considered significant.

RESULTS

Nine eyes of 6 patients that had undergone an 8-cut RK 15 to 23 years before the CXL were included in the study. The mean patient age at the time of the procedure was 52 ± 11 years (range, 29–61 years). Three eyes (2 eyes of the same patient) had a myopic manifest refraction spherical equivalent

(MRSE), and 6 eyes had hyperopic MRSE pre-CXL. The safety index, calculated as the average CDVA 12 months post-CXL divided by the pre-CXL CDVA, was 1.2. One patient had undergone cataract extraction 11 months after the CXL procedure, after stabilization of her topography and refraction. In another patient, the 12-month follow-up visit is pending. Therefore, these 2 patients were excluded from the 12-month post-CXL analysis.

In 5 patients (8 out of 9 eyes), discontinuation of diurnal visual fluctuation was reported between 6 and 12 months after CXL. The only patient in whom the diurnal fluctuations continued was a patient who had CXL in 1 eye only, 22 years post the 8-cut RK and 15 years post additional astigmatic keratotomy incisions. A second patient had satisfactory subjective and objective results and wanted to pursue further refractive surgery. A wavefront-guided photorefractive keratectomy (WG-PRK) surgery was carried out in both eyes 18 months after the CXL. Unfortunately, his visual fluctuations reappeared after the WG-PRK and continued despite a second round of CXL 6 months after the WG-PRK.

Visual Acuity (UDVA and CDVA) and MRSE

An average UDVA gain of 0.3 logMAR lines was noted 6 months ($P = 0.004$, 9 eyes) post-CXL, from a mean UDVA of 0.8 ± 0.3 logMAR (range, 0.4–1.3 logMAR) preoperatively to 0.5 ± 0.2 logMAR (range, 0.3–0.9 logMAR) postoperatively. An average gain of 0.1 logMAR line (although not statistically significant; $P = 0.3$, 7 eyes) was noted after 12 months of the follow-up from a mean UDVA of 0.7 ± 0.3 logMAR (range, 0.4–1.2 logMAR) preoperatively to 0.6 ± 0.2 logMAR (range, 0.3–1 logMAR) postoperatively. The average UDVAs at the 3- and 6-month follow-up visits were 0.6 ± 0.25 logMAR (range, 0.3–0.9 logMAR) and 0.5 ± 0.21 logMAR (range, 0.3–0.9 logMAR, $P = 0.1$), respectively. An average CDVA gain of 0.2 logMAR lines was noted 6 months post-CXL (although not statistically significant, $P = 0.1$, 9 eyes) from 0.3 ± 0.4 logMAR (range, -0.1 to 1 logMAR) preoperatively to 0.1 ± 0.1 logMAR (range, -0.1 to 0.3 logMAR). An average gain of 0.1 logMAR line was noted after 12 months of the follow-up (although not statistically significant, $P = 0.5$, 7 eyes) from a mean CDVA of 0.2 ± 0.4 logMAR (range, -0.1 to 1 logMAR) preoperatively to 0.1 ± 0.1 logMAR (range, 0–0.3 logMAR) postoperatively. The average CDVAs at the 3- and 6-month follow-up visits were 0.1 ± 0.1 logMAR (range, 0–0.3 logMAR) and 0.1 ± 0.1 logMAR (range, -0.1 to 0.3 logMAR, $P = 0.5$), respectively. Figure 1 shows the change in the mean UDVA and CDVA throughout the 6- and 12-month postoperative follow-up period in 9 eyes and 7 eyes, respectively.

The mean MRSE increased from $+1.0 \pm 3.9$ diopters (D) (range, -5.1 to +4.9 D) preoperatively to $+2.8 \pm 3.0$ D (range, -1.38 to 6.75 D) after 6 months of the follow-up ($P = 0.01$, 9 eyes). Similarly, the mean MRSE increased from $+1.4 \pm 3.8$ D (range, -5.1 to 4.9 D) preoperatively to $+2.5 \pm 2.5$ D (range, -1.4 to +5.6 D) after 12 months of the follow-up (although not statistically significant, $P = 0.1$, 7 eyes). The mean MRSEs at the 3- and 6-month follow-up visits were 3.1 ± 3.1 D (range, -3.1 to +6.8 D) and 2.8 ± 3.0 D

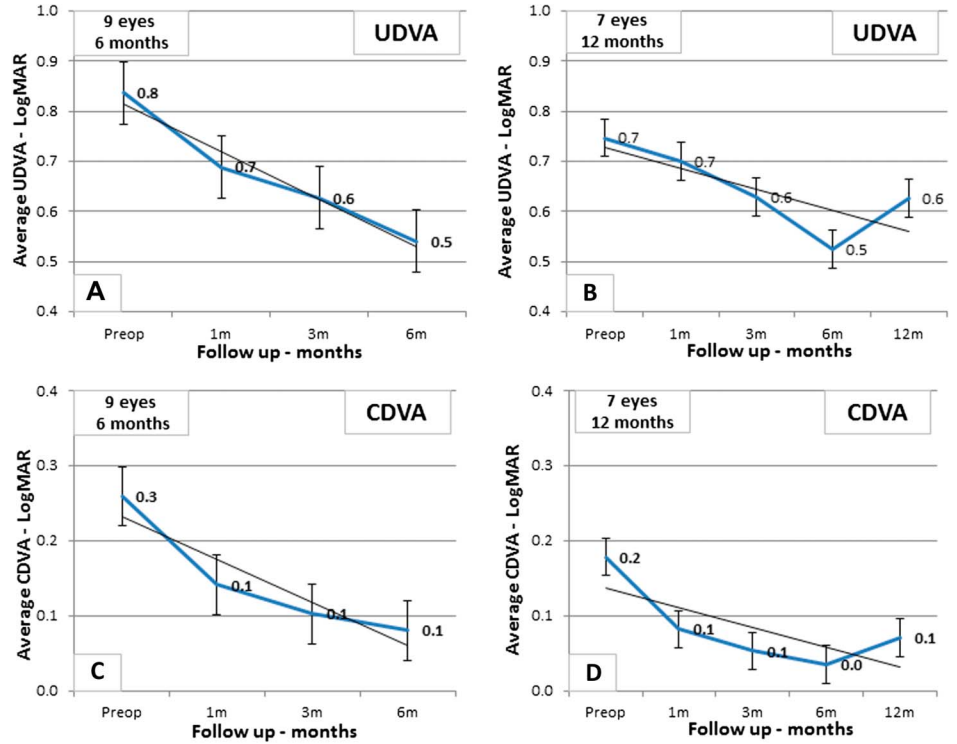


FIGURE 1. Timeline for UDVA and CDVA over 6 months (A, C) and 12 months (B, D) of the follow-up, respectively. The regression line and standard error bars are plotted.

(range, -1.4 to +6.8, $P = 0.8$), respectively. Figure 2 shows the change in the mean MRSE throughout the 6- and 12-month postoperative follow-up period in 9 eyes and 7 eyes, respectively.

Corneal Astigmatism

A mean decrease of 0.3 D ($P = 0.03$, 9 eyes) in corneal astigmatism from 2.1 ± 1.6 D (range, 0.25–4.5 D) to 1.8 ± 1.5 D (range, 0.25–4 D) was noted 6 months after the CXL. A mean decrease of 0.4 D (although not statistically significant, $P = 0.06$, 7 eyes) in corneal astigmatism from 2.3 ± 1.7 D (range, 0.25–4.5 D) to 1.9 ± 1.5 D (range, 0.43–4 D) was noted 12 months after the CXL. The average corneal astigmatism at the 3- and 6-month follow-up visits was 1.8 ± 1.3 D (range, 0.5–3.7 D) and 1.8 ± 1.4 D (range, 0.25–4 D), respectively ($P = 0.96$).

Average Keratometry

A mean decrease of 0.9 D ($P = 0.04$, 9 eyes) in the average keratometry from 39.2 ± 5.6 D (range, 34.2–50.3 D) to 38.3 ± 4.6 D (range, 33.8–47 D) was noted 6 months after the CXL. Similarly, a mean decrease of 1.0 D (although not statistically significant, $P = 0.06$, 7 eyes) in the average keratometry from 40.1 ± 6.0 D (range, 35.1–50.3 D) to 39.1 ± 4.85 D (range, 35.1–47.0 D) was noted at the 12-month visit. The mean average keratometry values at the 3- and 6-month follow-up visits were 38.84 ± 5.39 D (range, 33.86–47.88 D) and 38.25 ± 4.59 D (range, 33.75–47.0 D), respectively ($P = 0.32$). Figure 3 shows the change in the mean corneal astigmatism and average keratometry throughout the 6- and 12-month postoperative follow-up period in 9 eyes and 7 eyes, respectively.

The summary of the change in the primary outcomes after 6 and 12 months of the follow-up is given in Table 1.

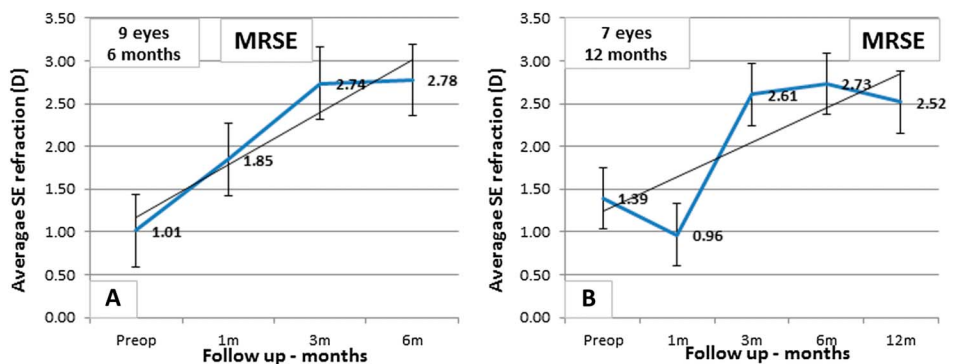


FIGURE 2. Timeline for manifest refraction spherical equivalent (MRSE) over 6 months (A) and 12 months (B) of the follow-up in 9 and 7 eyes, respectively. The regression line and standard error bars are plotted.

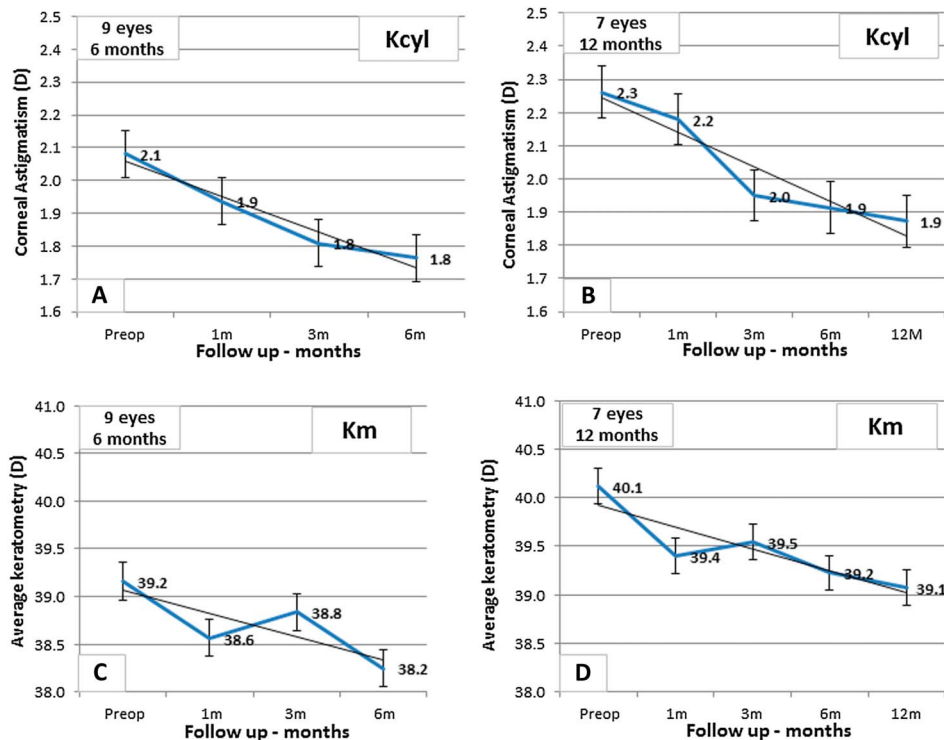


FIGURE 3. Timeline for corneal astigmatism (K_{cyl}) and average keratometry (K_m) over 6 months (A, C) and 12 months (B, D) of the follow-up, respectively. The regression line and standard error bars are plotted.

DISCUSSION

RK has many drawbacks including the occurrence of a hyperopic shift, low long-term predictability, and corneal instability, all leading to visual fluctuations and a constant change in the refractive error.^{1-3,15,16} Consequently, in the early 1990s, RK was abandoned in favor of other refractive treatment modalities. Patients experiencing a decrease in their vision after RK surgery are now seeking a remedy for their progressively worsening and/or fluctuating vision. Our study focuses on the possibility of CXL as a biomechanical stabilizer after RK surgery. Our data indicate that CXL is an effective and safe method for treating refractive instability in RK-operated patients.

CXL is not a refractive procedure despite its vision ameliorating effect. As has been proven in patients with KC,^{13,17} CXL may cause flattening of the cone and halt the

progression of this ectatic disease. However, hyperopic KC is extremely rare, and KC is usually associated with high myopia and irregular astigmatism,^{18,19} as opposed to that seen in post-RK patients. Hence, a flattening of the corneal curvature by CXL reduces the myopic error and the corneal astigmatism in patients with KC, which results in a lower refractive error and a better UDVA. On the contrary, post-RK corneas usually present with a hyperopic refractive error after several years.^{2,3,15} Therefore, CXL with its flattening effect may often cause an even higher hyperopic refractive error. This was noted in our data, as the mean MRSE increased with a reciprocal decrease in the average K readings. Despite this fact, there was significant improvement in the mean UDVA up to 12 months after the procedure. One possible explanation for this is the fact that the subepithelial fibrosis around the RK incisions, which can occasionally involve the visual axis, is at least partially scraped off before CXL (during the epithelial debridement stage of the treatment). Moreover, the remodeling process that takes place after CXL may reduce higher-order aberrations²⁰ leading to a better UDVA despite the higher MRSE. However, we did not control for higher-order aberrations. Lastly, CXL may restrict fluctuations in corneal stability to a certain extent, again contributing to an improved visual experience.

Numerous studies have reported the outcome of conventional LASIK^{4,5} and PRK^{8,12,21,22} to correct myopic or hyperopic regression after RK with variable results. Recently, Ghanem et al²³ have shown encouraging results in 61 eyes with a 2-year follow-up after a WG-PRK with mitomycin C (MMC) for hyperopia post-RK. In their study, WG-PRK proved to be effective, predictable, and safe for the treatment of hyperopia and hyperopic astigmatism after RK.

TABLE 1. Change (Δ) in Primary Outcomes: UDVA, CDVA, Average Keratometry, Corneal Astigmatism, and MRSE After 6 months in 9 Eyes and After 12 months in 7 Eyes (*P* values are Noted in Brackets)

Primary Outcomes	9 Eyes With 6 mos of Follow-up	7 Eyes With 12 mos of Follow-up
UDVA Δ (gain)—logMAR lines (<i>P</i> value)	0.3 (0.004)	0.1 (0.3)
CDVA Δ (gain)—logMAR lines (<i>P</i> value)	0.2 (0.1)	0.1 (0.5)
Average <i>K</i> Δ —D (<i>P</i> value)	-0.9 (0.04)	-1 (0.06)
Corneal astigmatism Δ —D (<i>P</i> value)	-0.3 (0.03)	-0.4 (0.06)
MRSE Δ —D (<i>P</i> value)	+1.8 (0.01)	+1.1 (0.1)

There was a significant improvement in the UDVA, CDVA, and higher-order aberrations with a low incidence of visually significant corneal haze. However, despite the relatively long follow-up, RK-operated corneas can exhibit instability up to 10 years after the procedure^{1,15}; therefore, a 2-year follow-up may be too short to show definite stability. In addition, corneal refractive surgery could contribute to corneal instability because the residual stress-bearing stroma in post-RK eyes consists only of the 5% to 10% posteriormost stroma in the areas directly below the incisions.²⁴ In our opinion, any plan for refractive surgery in this subpopulation should be made only after achieving stabilization of corneal parameters and of vision, by means of a stabilizing procedure such as CXL. In KC, where biomechanical instability is of great concern, CXL has been shown to be effective and safe even after a very long follow-up period.²⁵ Similarly, CXL was shown to be effective in cases of corneal ectasia after LASIK is performed.²⁶ Post-RK corneas and KC share similar properties. In KC, there is progressive peripheral stromal thinning in the area of the cone that leads to constant change in the curvature of the cornea, especially when other factors, such as eye rubbing, are involved. Again, the stress-bearing stroma is considerably thin compared with that in normal corneas. Likewise, post-RK corneas exhibit a slow but progressive change in curvature and daily fluctuations in the corneal curvature.¹ After RK, central flattening along with peripheral steepening occurs. This, however, may continuously evolve and lead to a hyperopic shift.

As beneficial as CXL has proven to be in recent years, there are, as always, associated complications.²⁷ These include delayed epithelial healing, endothelial cell loss in corneas thinner than 400 μm , secondary corneal infections, corneal melt, and a reported case of gaping of the radial incisions after CXL in a post-RK patient.²⁸ None of our patients experienced any complications after the CXL. Theoretically, there may be a higher risk of endothelial cell loss occurring in post-RK corneas because some segments of the cornea have a thickness much lesser than 400 μm —the safe thickness limit reported for this procedure.²⁹ Despite the fact that we did not control for the endothelial cell count in our patients, none of our patients exhibited corneal decompensation at any point in time post-CXL.

We have shown here that significant improvements in the UDVA, reduced corneal astigmatism, and flattening of corneal curvature were achieved after 6 months of the follow-up. Despite blunting of some of the effect that was achieved at the 6-month visit, there was still a trend toward favorable results (Table 1) for CXL in post-RK corneas after 12 months of follow-up. Accordingly, previous data have shown good outcomes after 6 months of follow-up after CXL for post-RK corneas.³⁰ However, a longer follow-up with larger cohorts is necessary to validate these findings and to show stability over longer periods of time.

In conclusion, it is observed that CXL is likely a safe and effective procedure for biomechanical corneal stabilization in RK-operated patients who experience visual deterioration. We recommend this procedure before planning any refractive surgery in this unique subpopulation. A protocol combining simultaneous CXL with PRK, such as the Athens

protocol³¹ for post-LASIK ectasia patients, may be an option for the treatment of post-RK corneas.

REFERENCES

- Kemp JR, Martinez CE, Klyce SD, et al. Diurnal fluctuations in corneal topography 10 years after radial keratotomy in the Prospective Evaluation of Radial Keratotomy Study. *J Cataract Refract Surg*. 1999;25:904–910.
- Deitz MR, Sanders DR, Raanan MG, et al. Long-term (5- to 12-year) follow-up of metal-blade radial keratotomy procedures. *Arch Ophthalmol*. 1994;112:614–620.
- Waring GO III, Lynn MJ, McDonnell PJ. Results of the prospective evaluation of radial keratotomy (PERK) study 10 years after surgery. *Arch Ophthalmol*. 1994;112:1298–1308.
- Afshari NA, Schirra F, Rapoza PA, et al. Laser in situ keratomileusis outcomes following radial keratotomy, astigmatic keratotomy, photorefractive keratectomy, and penetrating keratoplasty. *J Cataract Refract Surg*. 2005;31:2093–2100.
- Sinha R, Sharma N, Ahuja R, et al. Laser in-situ keratomileusis for refractive error following radial keratotomy. *Indian J Ophthalmol*. 2011;59:283–286.
- Koch DD, Maloney R, Hardten DR, et al. Wavefront-guided photorefractive keratectomy in eyes with prior radial keratotomy: a multicenter study. *Ophthalmology*. 2009;116:1688–1696 e2.
- Ghanem RC, Ghanem VC, de Souza DC, et al. Customized topography-guided photorefractive keratectomy with the MEL-70 platform and mitomycin C to correct hyperopia after radial keratotomy. *J Refract Surg*. 2008;24:911–922.
- Anbar R, Malta JB, Barbosa JB, et al. Photorefractive keratectomy with mitomycin-C for consecutive hyperopia after radial keratotomy. *Cornea*. 2009;28:371–374.
- Perente I, Utine CA, Cakir H, et al. Complicated flap creation with femtosecond laser after radial keratotomy. *Cornea*. 2007;26:1138–1140.
- Muñoz G, Albarrán-Diego C, Sakla HF, et al. Femtosecond laser in situ keratomileusis for consecutive hyperopia after radial keratotomy. *J Cataract Refract Surg*. 2007;33:1183–1189.
- Francesconi CM, Nosé RA, Nosé W. Hyperopic laser-assisted in situ keratomileusis for radial keratotomy induced hyperopia. *Ophthalmology*. 2002;109:602–605.
- Nassaralla BA, McLeod SD, Nassaralla JJ Jr. Prophylactic mitomycin C to inhibit corneal haze after photorefractive keratectomy for residual myopia following radial keratotomy. *J Refract Surg*. 2007;23:226–232.
- Brooks NO, Greenstein S, Fry K, et al. Patient subjective visual function after corneal collagen crosslinking for keratoconus and corneal ectasia. *J Cataract Refract Surg*. 2012;38:615–619.
- Wollensak G, Spoerl E, Seiler T. Riboflavin/ultraviolet-a-induced collagen crosslinking for the treatment of keratoconus. *Am J Ophthalmol*. 2003;135:620–627.
- Charpentier DY, Garcia P, Grunewald F, et al. Refractive results of radial keratotomy after 10 years. *J Refract Surg*. 1998;14:646–648.
- Waring GO. Radial keratotomy predictability. *Ophthalmology*. 1994;101:415–416.
- Caporossi A, Mazzotta C, Baiocchi S, et al. Long-term results of riboflavin ultraviolet a corneal collagen cross-linking for keratoconus in Italy: the Siena eye cross study. *Am J Ophthalmol*. 2010;149:585–593.
- Martin R. Keratoconus with high hyperopia. *Eye Contact Lens*. 2009;35:159–162.
- Abad JC, Awad A, Kurstin JM. Hyperopic keratoconus. *J Refract Surg*. 2007;23:520–523.
- Reinstein DZ, Gobbe M, Archer TJ, et al. Epithelial thickness profile as a method to evaluate the effectiveness of collagen cross-linking treatment after corneal ectasia. *J Refract Surg*. 2011;27:356–363.
- Shalaby A, Kaye GB, Gimbel HV. Mitomycin C in photorefractive keratectomy. *J Refract Surg*. 2009;25:S93–S97.
- Joyal H, Grégoire J, Faucher A. Photorefractive keratectomy to correct hyperopic shift after radial keratotomy. *J Cataract Refract Surg*. 2003;29:1502–1506.
- Ghanem RC, Ghanem VC, Ghanem EA, et al. Corneal wavefront-guided photorefractive keratectomy with mitomycin-C for hyperopia after radial keratotomy: two-year follow-up. *J Cataract Refract Surg*. 2012;38:595–606.

24. Dawson DG, Randleman JB, Grossniklaus HE, et al. Corneal ectasia after excimer laser keratorefractive surgery: histopathology, ultrastructure, and pathophysiology. *Ophthalmology*. 2008;115:2181–2191 e1.
25. Kanellopoulos AJ. Long term results of a prospective randomized bilateral eye comparison trial of higher fluence, shorter duration ultraviolet A radiation, and riboflavin collagen cross linking for progressive keratoconus. *Clin Ophthalmol*. 2012;6:97–101.
26. Poli M, Cornut PL, Balmitgere T, et al. Prospective study of corneal collagen cross-linking efficacy and tolerance in the treatment of keratoconus and corneal ectasia: 3-year results. *Cornea*. 2013;32:583–590.
27. Dhawan S, Rao K, Natrajan S. Complications of corneal collagen cross-linking. *J Ophthalmol*. 2011;2011:869015.
28. Abad JC, Vargas A. Gaping of radial and transverse corneal incisions occurring early after CXL. *J Cataract Refract Surg*. 2011;37:2214–2217.
29. Spoerl E, Mrochen M, Sliney D, et al. Safety of UVA-riboflavin cross-linking of the cornea. *Cornea*. 2007;26:385–389.
30. Mazzotta C, Baiocchi S, Denaro R, et al. Corneal collagen cross-linking to stop corneal ectasia exacerbated by radial keratotomy. *Cornea* 2011; 30:225–228.
31. Kanellopoulos AJ, Binder PS. Management of corneal ectasia after LASIK with combined, same-day, topography-guided partial transepithelial PRK and collagen cross-linking: the Athens protocol. *J Refract Surg*. 2011;27:323–331.